

Endodontic perforation repair with light-cured glass ionomer

Manal Farea,¹ Adam Husein,² Cornelis H Pameijer³

The aim of endodontic therapy is for complete debridement of pulpal tissues, thorough cleaning and shaping, and total obturation of the root canal space, which will subsequently provide an effective barrier to prevent passage of micro-organisms and their by-products into periodontal spaces and periapical tissues (Gutmann, 2002; Ingle and Bakland, 2002). Endodontic perforations interfere with this goal because of the presence of a communication with these tissues. Perforations may be caused by iatrogenic dentistry, resorptive processes, or caries and can be diagnosed through direct observation of bleeding, indirect bleeding assessment by means of a paper point,

radiographs, and an apex locator (Alhadainy, 1994). Perforation defects may be repaired by non-surgical or surgical techniques. Surgical repair is indicated when access through the canal is impossible (Stock and NG, 2004).

Various materials have been utilized for perforation repairs, such as zinc oxide and eugenol-based cements (IRM and EBA), mineral trioxide aggregate (MTA), amalgam, glass ionomers, gutta percha, calcium hydroxide alone, and calcium hydroxide or Klorapercha N-O-covered with amalgam or gutta percha, hydroxyapatite and plaster of Paris (Alhadainy, 1994; Alhadainy and Himel 1994; Mittal et al, 1999).

The ideal material for treating endodontic perforations should be non-toxic, non-absorbable, radiopaque, bacteriostatic or bactericidal and easy to apply. The material should also provide a tight seal against microleakage at the perforation site.

Of the materials mentioned above, MTA is arguably the most suitable material for managing perforations (Pitt Ford, McKendry, 2002) as it has many favorable properties. However, one of the limitations of MTA is its extended setting time and difficulty in handling. The

¹ Manal Farea, BDS, MSc Conservative Department, School of Dental Sciences, University Sains Malaysia, Kelantan, Malaysia.

² Adam Husein, BDS, D Clin Dent, Conservative Department, School of Dental Sciences, University Sains Malaysia, Kelantan, Malaysia.

³ Cornelis H Pameijer DMD, MScD, DSc, PhD Professor Emeritus University of Connecticut, School of Dental Medicine, Farmington, CT, USA.

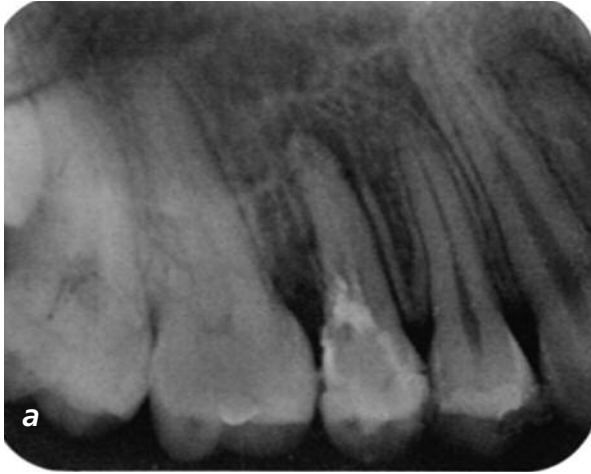


Figure 1a: Pre-operative radiograph.

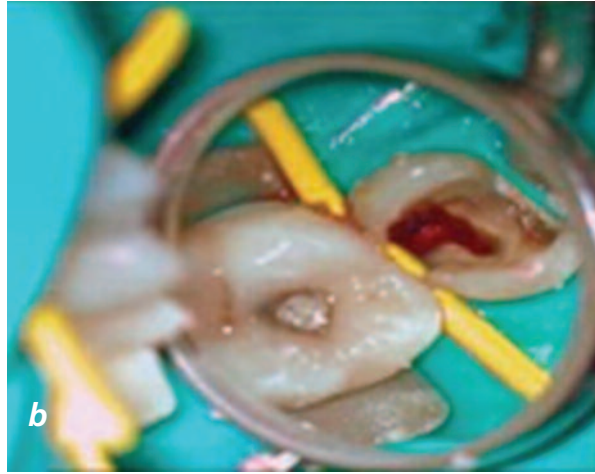


Figure 1b: Bleeding from the perforation site.

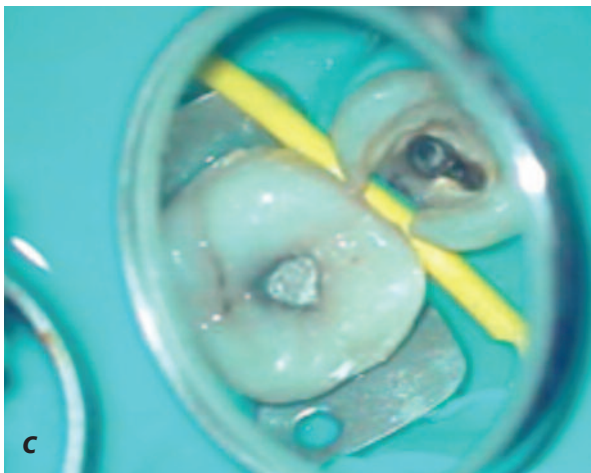

Figure 1c: Perforation site was repaired with light-cured glass ionomer.

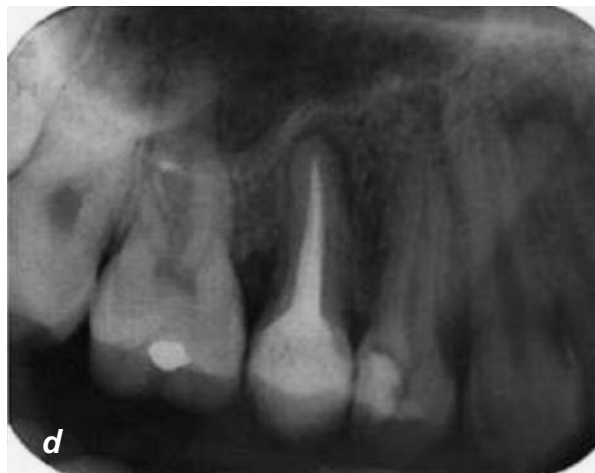

Figure 1d: One year post perforation repair and eight months post canal obturation showing signs of healing and intact repaired site.

material is more suitable for box-like cavities where it can be lightly packed. This is a drawback not only for potential users but for experienced operators as well.

In clinical situations when this material is unavailable, clinicians are forced to resort to other materials when trying to save a perforated tooth. The material of choice must exhibit basic properties such as biocompatibility, ability to adhere to tooth structure for adequate sealing and ease of application.

In this case report, two cases of perforation repair are reported in which a light-cured glass ionomer was used. Post-operative evaluations were conducted after one and two years.

Case report one

A 24-year-old female was referred to the Hospital University Sains Malaysia's Specialist Dental Clinic for the treatment of pain and swelling associated with her maxillary right second premolar. The tooth had a six-month history of intermittent pain following placement of a composite resin restoration and was eventually endodontically treated by her previous dentist. However, the problem persisted following endodontic treatment.

Her previous medical history was unremarkable. Extra-oral examination revealed no abnormalities. Intra-oral examination showed that the tooth had a large

disto-occlusal glass ionomer restoration extending subgingivally. The tooth was tender to vertical percussion and apical palpation and had class I mobility. Periodontal probing showed a 6mm pocket at the distal of the tooth. A buccal fistula was present on the attached gingiva between the tooth and the first molar. Vitality testing was not performed as the tooth already had a history of root canal treatment.

Radiographic findings showed poor endodontic treatment with incomplete obturation of the canal, a periapical radiolucency, widening of the periodontal ligament, mesial loss of lamina dura and distal loss of alveolar bone crest (Figure 1a). A diagnosis of a failed root canal treatment and chronic periapical periodontitis with possible distal perforation was made. All possible treatment options were discussed and the patient expressed the preference to retain the tooth. Endodontic re-treatment with possible perforation repair by using light-cured glass ionomer (GC Fuji Lining LC, GC, Japan) was offered to the patient and she agreed to the treatment plan. She was informed that the more suitable material (MTA) for perforation repair was not available in the clinic.

At the next treatment visit, the tooth was isolated with rubber dam and subsequent treatment steps were performed under a 2.5x magnification using a microscope (Zeiss operating microscope; Carl Zeiss, Jena, Germany). After removal of the existing restoration, a distal perforation of 3mm in width through to the base of the pulp chamber was detected through probing and by observing the presence of blood (Figure 1b). Bleeding was arrested by rinsing with 1% sodium hypochlorite and pressure packing with gauze. The next step was the removal of debris and remaining caries from the perforation site. After rinsing the cavity with distilled water followed by drying, a dentin conditioner (GC Corporation, Tokyo, Japan) was applied to the dentin surrounding the perforation and left in place for 10 seconds, followed by rinsing with distilled water for five seconds and lightly drying with air and a sterile cotton pellet. The perforation defect was then repaired using a light-cured glass ionomer, GC Fuji Lining LC (GC, Japan) following the manufacturer's instructions. The material was mixed to a slightly running consistency for ease of application and was carried into place by using a periodontal probe. The perforation site was gradually filled up from the base with the material covering about 2-3mm of the

surrounding dentin (Figure 1c) and then light-cured (Bludent LED, Plovdiv, Bulgaria). Final thickness of the material was about 2mm. Care was taken not to occlude the orifices of the buccal and palatal canals. Subsequently, conventional endodontic re-treatment procedures were carried out. Remnants of the endodontic filling material were conventionally removed by using 32mm stainless steel #2 and #3 Gates Glidden drills (Premier Dental Co., Norristown, PA) and chloroform (Merck, Darmstadt, FRG). The canal was irrigated with 1% sodium hypochlorite and dried with paper points (Kerr Absorbent Points, USA). Calcium hydroxide (PD, Washington, USA) was placed as intracanal medication followed by a sterile cotton Caviton (GC, Japan) and a light-cured glass ionomer restoration (Fuji II, GC, Japan). The tooth was adjusted for minimal occlusal contact.

At three months review, the patient reported no signs and symptoms. There was no tenderness to percussion and palpation; the draining sinus had healed and the distal pocket depth was 3mm and the tooth had reduced mobility. Inspection of the perforation site was performed by removing the temporary restoration under rubber dam. It was noted that the repaired perforation was intact (visual and tactile examination) and clinically there were no signs of leakage.

Conventional root canal treatment was then continued with mechanical preparation of the canal with a step-back technique, followed by calcium hydroxide intracanal medication. Obturation was completed one month later with AH 26 (Dentsply De Trey GmbH, Konstanz, Germany) and cold lateral condensation technique of gutta percha (Dentsply Maillefer, Ballaigues, Switzerland). A year after the first visit, the tooth remained asymptomatic (Figure 1d). Regular recalls were continued at six-month intervals. The patient was advised of the necessity of a crown to restore the tooth.

Case report two

A 23-year-old male was referred to the Hospital University Sains Malaysia's Specialist Dental Clinic for the management of an endodontic perforation of his lower left second molar. At the initial visit, he complained about swelling, mobility and moderate to severe pain. He stated that the endodontic treatment had not yet been completed. His medical history was unremarkable. Extra-oral examination revealed no

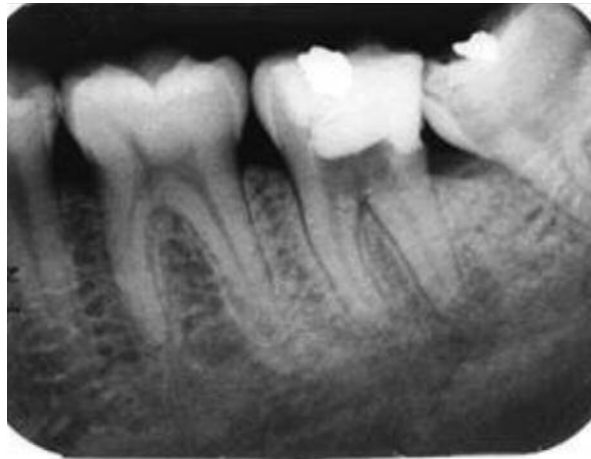

Figure 2a: Tooth 37 showing periapical radiolucency with furcal perforation.

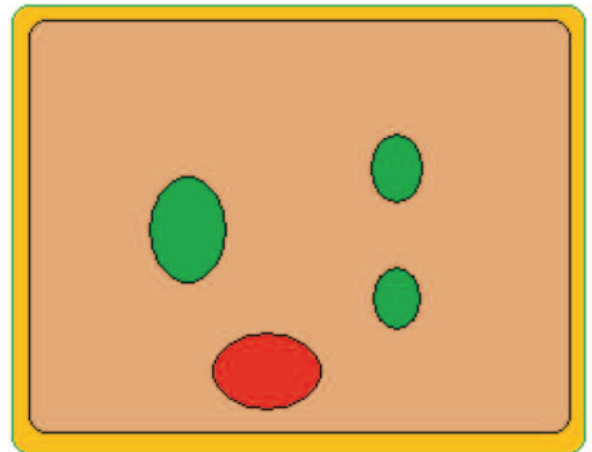


Figure 2b: Illustrated perforation site lingually.

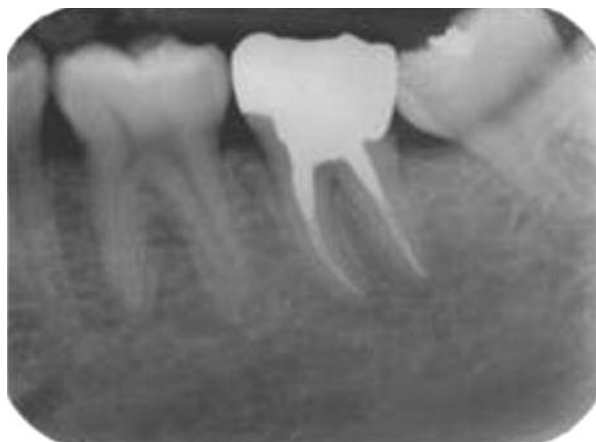

Figure 2c: Two years periapical radiograph revealed complete bone formation at the apex and furcation.

abnormalities. Intra-orally, tooth 37 presented with a large disto-occlusal glass ionomer restoration, distal caries, class I-II mobility, buccal and lingual swelling and an abscess. Periodontal probing showed 5mm pockets on the lingual opposite bifurcation area. The tooth was also tender to vertical percussion and apical palpation. Vitality testing was omitted as the tooth already had undergone initial endodontic treatment.

An intra-oral periapical radiograph revealed areas of radiolucencies associated with the furcation and distal root (Figure 2a). A diagnosis of acute periapical

periodontitis and abscess formation with a possible lingual furcation perforation was made. All possible treatment options were presented to the patient and he was advised of the condition and poor prognosis of the tooth. However, he insisted that attempts be made to save the tooth and agreed to the perforation repair with a light-cured glass ionomer followed by definitive endodontic and restorative treatment. The patient was also informed about the unavailability of the more suitable material (MTA) for perforation repair in the clinic.

Treatment conditions were similar as described in case report one. Upon establishing access and removal of all existing restorative material and caries, a round perforation defect measuring about 2mm in diameter was detected on the pulpal floor towards the lingual aspect of the tooth (Figure 2b). Unlike the previous case, the perforation showed minor hemorrhaging and had no caries. One percent NaOCl irrigation followed by pressure packing with sterile gauze as described in case report one was used to achieve hemostasis. After rinsing with distilled water and drying, the perforation site was etched with a dentin conditioner (GC Corporation, Tokyo, Japan), which was applied to the surrounding dentin for 10 seconds, followed by rinsing with distilled water for five seconds and light air drying. Subsequently, the perforation site was repaired with a

light-cured glass ionomer (GC, Tokyo, Japan). Mixing and application was similar to what has been described in case report one. The perforation site was gradually filled up with the material covering about 2-3mm of the surrounding dentin and then light-cured (Bludent LED, Plovdiv, Bulgaria). Final thickness of the material was about 2mm. Care was taken not to occlude the orifices of the root canals.

Subsequently, conventional endodontic treatment was performed consisting of cleaning and irrigating with 1% sodium hypochlorite and drying with paper points (Kerr Absorbent Points, USA). Calcium hydroxide (PD, Washington, USA) was placed as intra-canal medication followed by a sterile cotton pellet, Caviton (GC, Japan) and a light-cured glass ionomer restoration (Fuji II, GC, Japan). The tooth was adjusted for minimal occlusal contact.

At the three-month recall the patient was asymptomatic. Intra-oral examination showed that the tooth was no longer tender to percussion and palpation. Buccal and lingual swelling had subsided and tooth mobility was <1. Upon probing, the pocket depth in the lingual furcation area now measured 3mm. After removal of the restoration under rubber dam, examination of the perforation site (visual and tactile) showed an intact repaired perforation with no clinical signs of leakage (foul odor).

Conventional endodontic treatment was then continued with mechanical preparation of the canal using a rotary crown-down technique (ProTaper, Dentsply Maillefer). Canal preparation was completed with up to a F3 bur. Calcium hydroxide was used as intra-canal medication. Obturation was completed one-month later with AH 26 (Dentsply De Trey GmbH) and cold lateral condensation of gutta percha (Dentsply Maillefer, Ballaigues, Switzerland). The restorative treatment consisted of an amalgam post and core and complete metal crown. At a one-year post-operative visit the patient presented with an asymptomatic tooth. Regular recalls were carried out at six-month intervals. Two years after treatment, the patient presented with a normal functioning tooth (Figure 2c).

Discussion

Maintaining the integrity of the natural dentition is essential for function and esthetics. Endodontic therapy can play a vital role in achieving this goal. Occasionally

technical problems do occur during endodontic treatment i.e. perforating a wall or floor of the pulp chamber or root canal during caries removal, during access cavity preparation, locating of canals and mechanical debridement. This can significantly impair the long-term prognosis of a tooth (Breault et al, 2000).

Different materials have been used for endodontic perforation repair and the search for an ideal perforation repair material is a challenge. A repair material has to be placed in intimate contact with hard tissues of the tooth and soft tissues of the periodontium. These materials may pose a threat to endodontic treatment outcome by causing local or systemic adverse effects, either through direct contact with or leaching of chemical components into the periodontal tissues and alveolar bone (Breault et al, 2000).

In this case report, a light-cured glass ionomer was chosen as an alternative to MTA. Light-cured glass ionomer is a small particle, hydrophilic, non-aqueous resin combined with a photo initiator and glass powder formulation. The advantages of this material are its insolubility in oral fluids, reasonable adhesion to tooth structure, high strength, and dual cure properties. Light-cured glass ionomers also offer the following attributes: low cure shrinkage, low thermal expansion, and extended fluoride release as found in traditional glass ionomers (Scherer, Dragoo, 1995; Dragoo, 1997).

Traditional clinical applications for light-cured glass ionomer include: erosive lesions in geriatric patients, fixed prosthetics and resin bonded retainer cementation, porcelain repair, bonded amalgam restorations, core material, and pediatric restorations (Scherer, Dragoo, 1995; Dragoo, 1997).

Dragoo (1997) demonstrated clinically and histologically the biocompatibility of this restorative material. The formation of an epithelial and connective tissue adherence to light-cured glass ionomer represents a significant advancement in the ability to restore previously considered hopeless teeth (Dragoo, 1997; Stock, NG, 2004). Dragoo's (1997) clinical and histological investigation of light-cured glass ionomer demonstrates a biocompatibility to both soft and hard tissues. As an additional benefit, fluoride release from light-cured glass ionomer may positively affect bacterial plaque biochemistry through an alteration of carbohydrate metabolism (Scherer, Dragoo, 1995). As

the material polymerizes with visible light, its setting is fast and controllable, thus improving performance and reducing messy handling.

This is in contrast to MTA, which has an extended setting time and requires careful handling. Based on the above, even an inexperienced operator will appreciate the handling of a light-cured glass ionomer as being less demanding. In addition, sealing and resistance to microleakage are predictable as the material through chelation, chemically bonds to both enamel and dentin (Mount, Hume, 1998), while the material has been proven to be biocompatible (Human, Love, 2003). Glass ionomer, as a restorative dental material, has been successfully utilized for treatments of tooth abfractions, external root resorption, and root perforation repair (Shuman, 1999, Silveira, Schez-Ayala, 2008). The present case reports have demonstrated an additional application. Based on its biologic compatibility, light-cured glass ionomer material may be considered to be part of the clinician's armamentarium for the treatment of endodontic perforations, especially when more suitable materials such as MTA are unavailable. Economically the glass ionomer material has a significant advantage over MTA and it should, therefore, be of interest to many practitioners. However, more evidence from randomized controlled clinical trials needs to be generated to assess whether a more conclusive valid recommendation can be made about the performance of light-cured glass ionomers for the repair of endodontic perforations.

References

- Alhadainy HA (1994) Root Perforations: A review of literature *Oral Surg Oral Med Oral Pathol* 78: 368-74
- Alhadainy HA, Himel VT (1994) An in vitro evaluation of plaster of Paris barriers used under amalgam and glass ionomer to repair furcation perforations *J Endod* 20: 449-52
- Breault LG, Fowler EB, Primack CBD (2000) Endodontic Perforation Repair with Resin-Ionomer: A Case Report *J Contemp Dent Pract* 1: 1-7
- Dragoo MR (1997) Resin-ionomer and hybrid-ionomer cements: Part II. Human clinical and histologic wound healing responses in specific periodontal lesions *Int J Periodontics Restorative Dent* 17: 75-87
- Gutmann JI (2002) *Pathways of the pulp* 8th ed. St Louis: Mosby
- Human CHJ, Love RM (2003) Biocompatibility of dental materials used in contemporary endodontic therapy: a review. Part 2. Root-canal-filling materials *Int Endod J* 36: 147-60
- Ingle JI, Bakland LK (2002) *Endodontic* 5th ed. London: BC Decker
- Mittal M, Chandra S, Chandra S (1999) An Evaluation of Plaster of Paris Barriers Used under Various Materials to Repair Furcation Perforations (In Vitro Study) *J Endod* 25: 385-88
- Mount GJ, Hume WR (1998) *Preservation and restoration of tooth structure* 1st ed. Mosby
- Pitt Ford TR, McKendry DJ (1995) Use of mineral trioxide aggregate for repair furcal perforations *Oral Surg Oral Med Oral Pathol* 79: 756-63
- Scherer W, Dragoo MR (1995) New subgingival restorative procedures with Geristore resin ionomer *Pract Periodontics Aesthet Dent Jan-Feb;7(1 Suppl):* 1-4
- Shuman IE (1999) Repair of a root perforation with a resin-ionomer using an intentional replantation technique *Gen Dent* 47: 392-5
- Silveira CMM, Schez-Ayala A, Lagravere MO, Pilatti GL, Gomes OMM (2008) Repair of furcal perforation with mineral trioxide aggregate: long-term follow-up of two cases *J Can Dent Assoc* 74: 729-33
- Stock CJR, NG Y-L (2004) *Endodontics* 3rd ed. Elsevier Mosby